

# “Learn Image Segmentation Basics with Hands-on Introduction to ITK-SNAP”

## RSNA 2017 Course RCB32



### RCB32

Tue, Nov 28 10:30-12:00 PM, Room S401CD

#### Presenters:

- Paul Yushkevich, PhD, University of Pennsylvania, Philadelphia, PA
- Philip Cook, PhD, University of Pennsylvania, Philadelphia, PA
- Jeff Rudie, MD PhD, University of Pennsylvania, Philadelphia, PA
- Andreas Rauschecker, MD PhD, University of Pennsylvania, Philadelphia, PA

#### Learning Objectives:

- To use a free interactive software tool ITK-SNAP to view and manipulate 3D medical image volumes such as multi-parametric MRI, CT and ultrasound.
- To label anatomical structures in medical images using a combination of manual and user-guided automatic segmentation tools.

#### Course Outline:

Monday	Presenter	Topic
10:30 - 10:45	Yushkevich	Introduction to Module I “Image Navigation and Manual Segmentation”
10:45 - 11:15		Hands-on exercises 1 and 2
11:15 - 11:30	Cook	Introduction to Module II “Semi-Automatic Segmentation”
11:30 - 12:00		Hands-on exercises 3 and 4

# MODULE I: Image Navigation and Manual Segmentation

## Exercise 1. Image Navigation Basics

---

### Learning Objectives

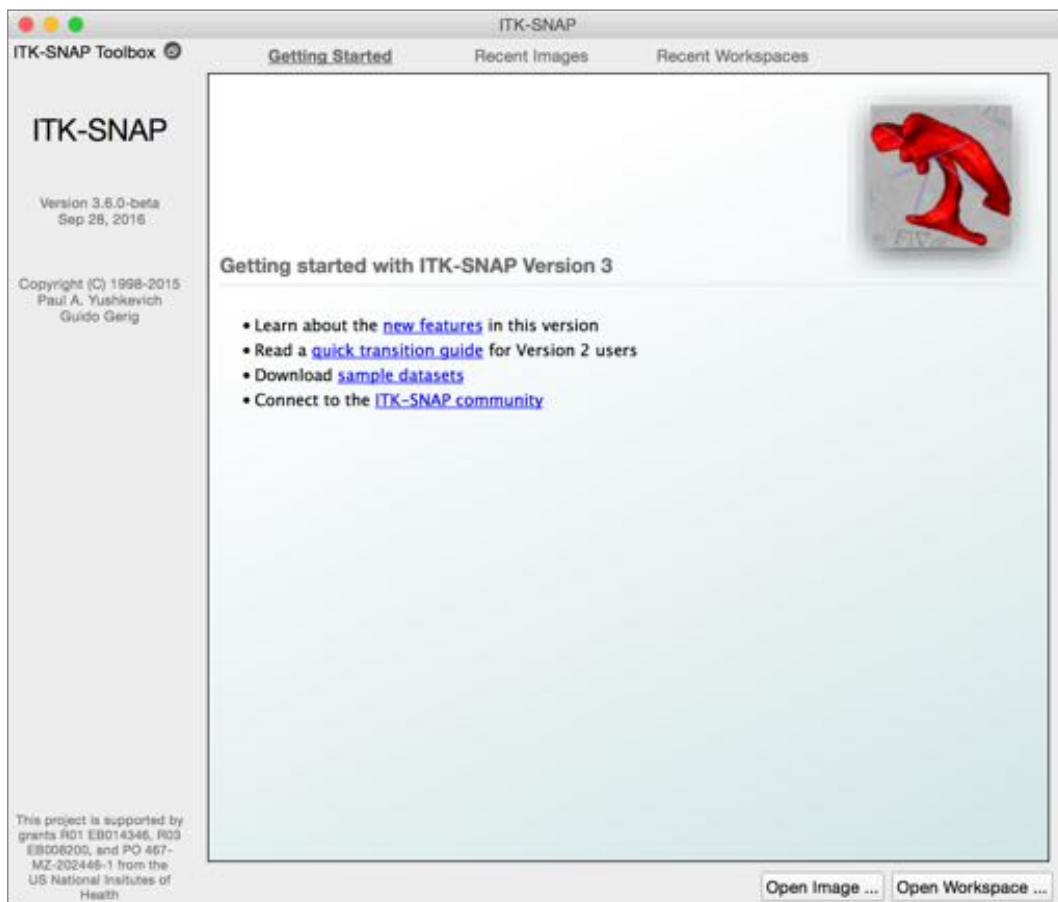
After completing this exercise, you will know how to

- Open 3D medical image files
- View orthogonal slices at different image locations
- Adjust image contrast
- Change zoom level and pan
- Open segmentation images
- Compute volumes and statistics

**Duration:** 15 minutes.

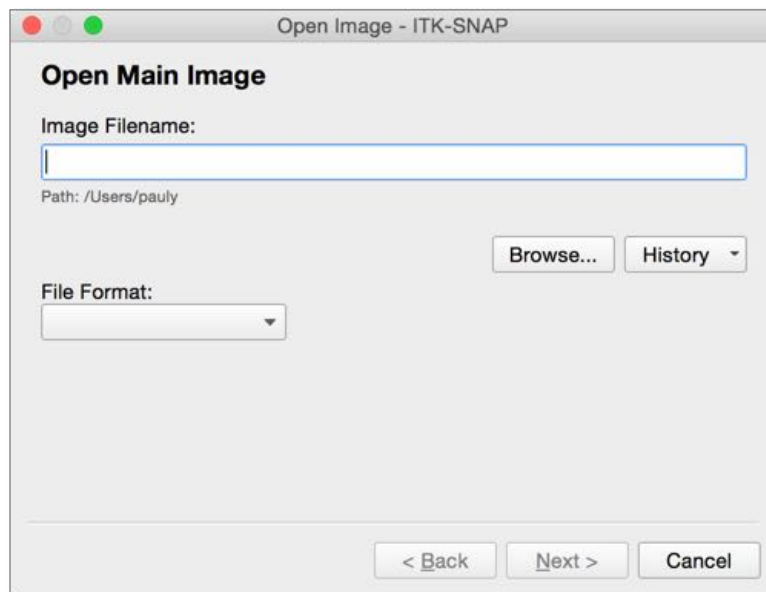
### Step 1. Launch ITK-SNAP

- Locate the ITK-SNAP icon on the Mac desktop
- Double-click the ITK-SNAP icon
- If the window like the one shown below does not open, get help from an instructor.



## Step 2. Open a Brain MRI

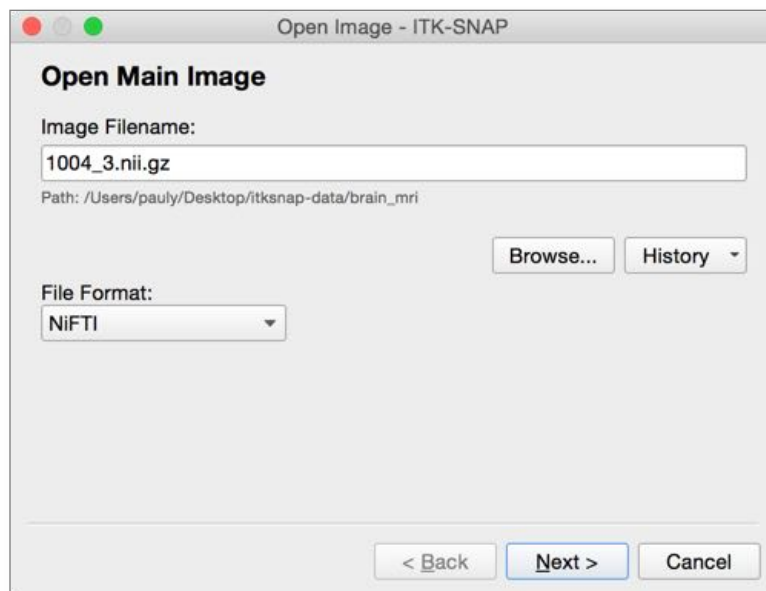
- Select *File->Open Main Image* from the menu. This will launch a wizard as shown below.



- Press *Browse* to search for the image
- Browse to the folder where the MRI data is stored:

**Desktop/itksnap-data/brain\_mri**

- Select the image **1004\_3.nii.gz** in this folder and press *Open*
- The wizard should now look like this:

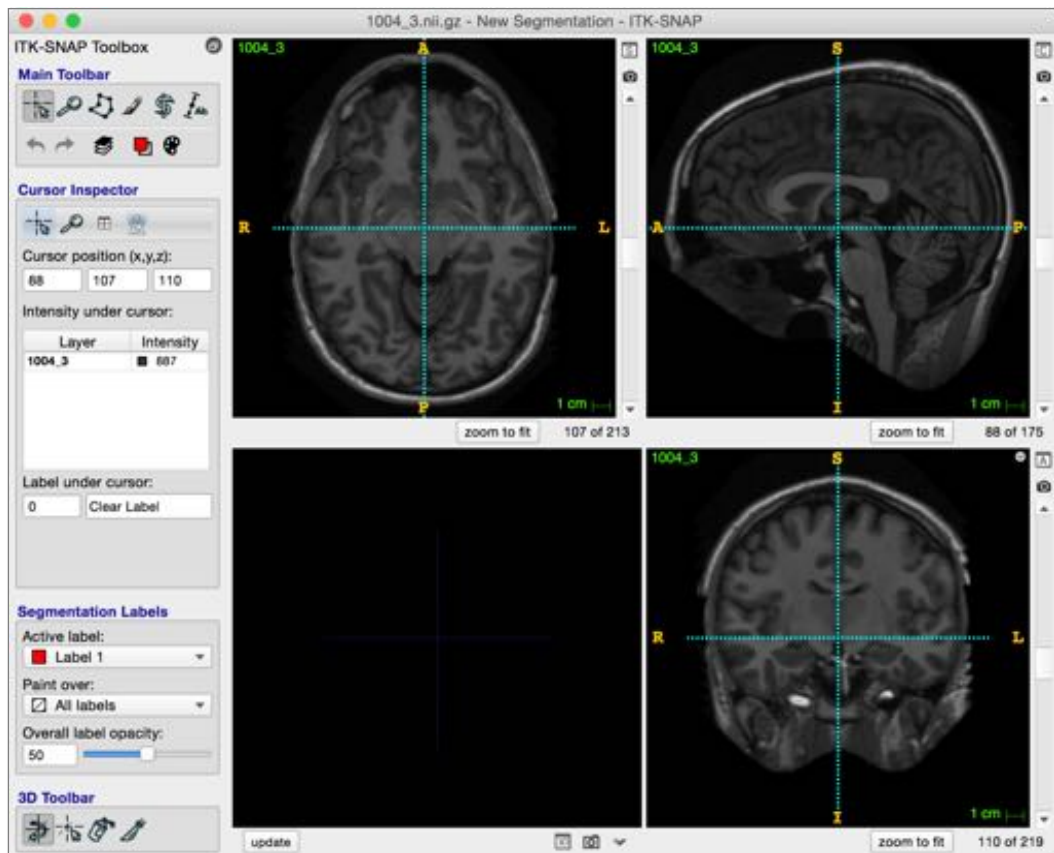


- Press Next. The wizard will go to the next page that shows summary information about the image.


*What are the dimensions of the image you just loaded?*

\_\_\_\_\_ by \_\_\_\_\_ by \_\_\_\_\_

- Press Finish. ITK-SNAP main window should now show three orthogonal views of a brain MRI scan.



### Step 3. Quick Contrast Adjustment

- Open the Layer Inspector (Tools->Layer Inspector or  button on the main toolbar)
- Click the Contrast tab
- Press Auto to adjust the contrast automatically.

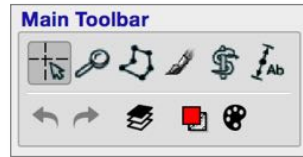*What are the level and window after automatic contrast adjustment?*

Level: \_\_\_\_\_ Window: \_\_\_\_\_

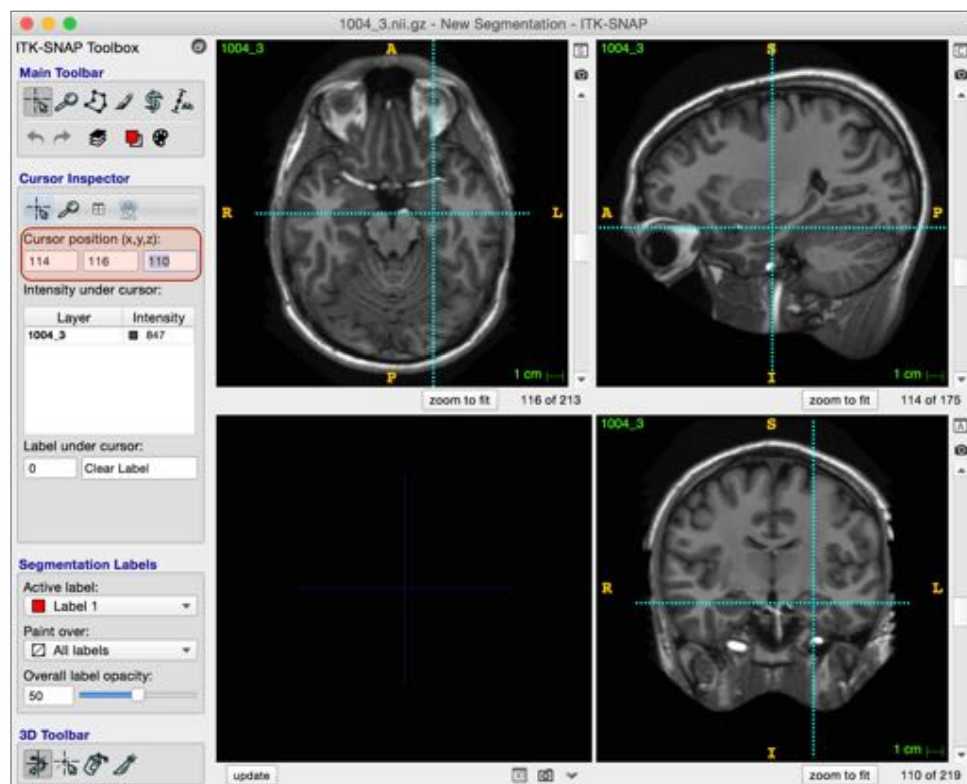
- Close the Layer Inspector

#### Step 4. Focus in on the Left Hippocampus

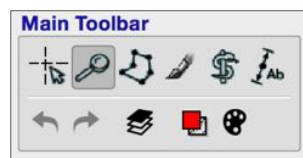- Make sure the Crosshair mode is selected as shown:



- Position the 3D cursor in the middle of the left hippocampus (see illustration below)
  - You can left-click in any of the three slice views to position the cursor
  - Or you can hold and drag the left mouse button for faster navigation
  - Or you can enter cursor position (114,116,110) in the Cursor Inspector panel (highlighted below)

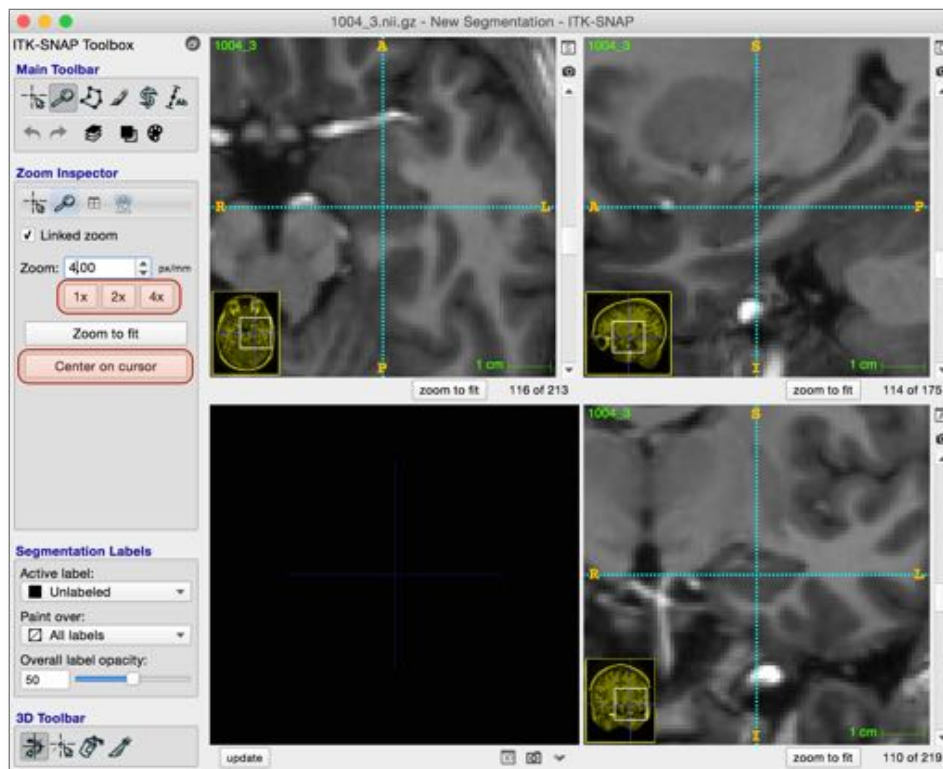


- Now select the Zoom/Pan mode from the main toolbar (shortcut 2)



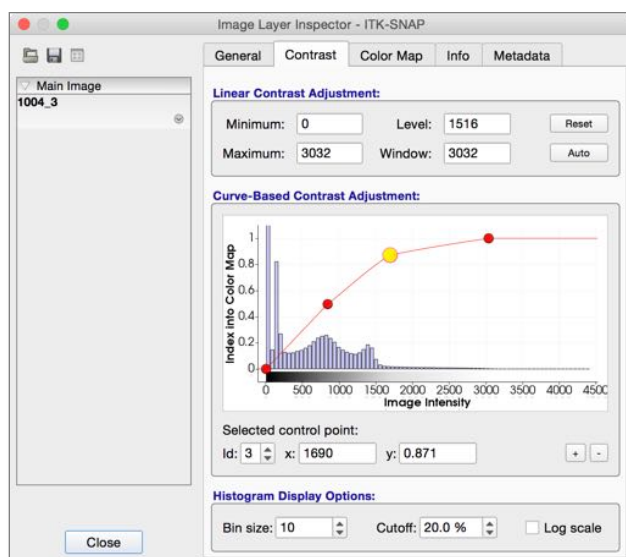
- Zoom in on the hippocampus
  - Hold the right mouse button in one of the slice views and drag up/down to zoom in or out
  - Or press the 4x button in the Zoom Inspector panel (highlighted below)

- Pan in each of the slice views so that the hippocampus is centered in each view
  - Hold and drag the left mouse button in each slice view until the hippocampus is centered
  - Or hold and drag the white rectangle in the yellow zoom thumbnail
  - Or press Center on Cursor in the Zoom Inspector (shortcut **c**)
- To move the cursor using the mouse, remember to go back to Crosshair Mode (shortcut **1**)



## Step 5. Fine Contrast Adjustment

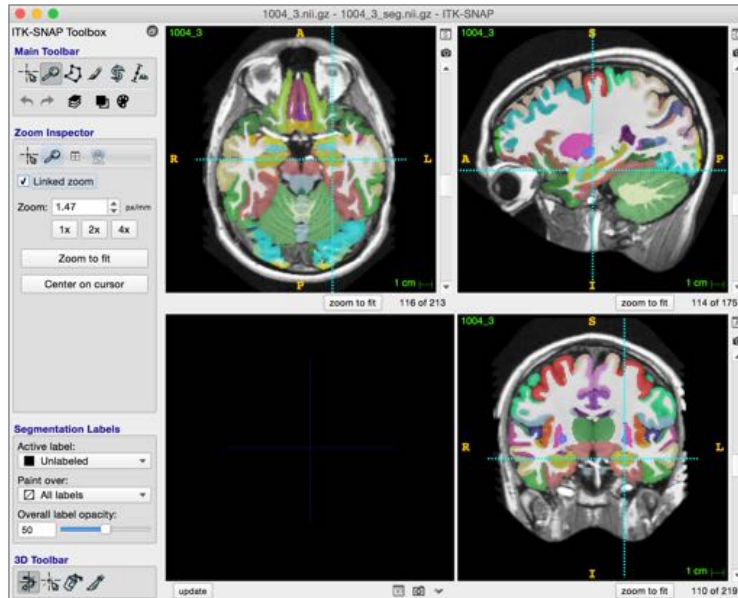
- Re-open the Layer Inspector window (shortcut is **⌘I**)
- Change the shape of the contrast curve to optimize contrast between tissues in the hippocampus region.
  - Click and drag the curve control points to adjust the shape of the curve
  - You can add more points with the '+' button
  - Close the Layer Inspector when you are done (shortcut **⌘W** closes dialog windows)





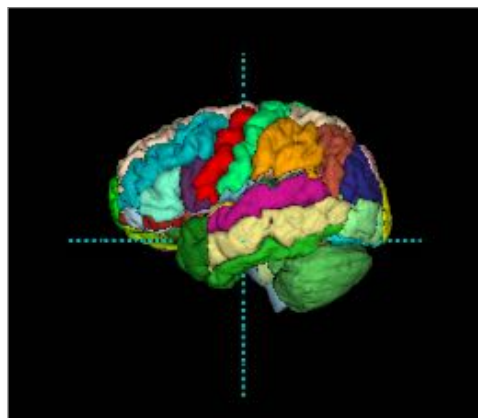
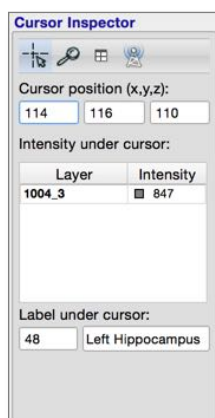
## Step 6. Load a Segmentation Image File

- Press Zoom to Fit in the Zoom Inspector to make the whole image visible again (shortcut ⌘F)
- In the main menu, select Segmentation->Open Segmentation to open a wizard (shortcut ⌘O)
- In the wizard, open the file **1004\_3\_seg.nii** in the same folder as the brain MRI image
- When you complete the wizard, the main ITK-SNAP window will show the segmentation



## Step 7. Load Segmentation Label Descriptions

- Select the Crosshair Tool in the Main Toolbar (shortcut 1).
  - Notice that in the Cursor Inspector, under Label Under Cursor, the label is “Label 48”
  - We will now load a set of label descriptions that have anatomical meaning
- In the main menu, select Segmentation->Import Label Descriptions
- In the window that opens, press Browse and select file **anat\_labels.txt**, then press Ok.
- Under Label Under Cursor, it should now say “Left Hippocampus”, as below
- In the lower left view (3D view) press the update button. You will see a rendering of the brain regions.



- Note: the default 3D visualization may produce a blocky visualization. To obtain a smoother visualization shown above, go to ITK-SNAP->Preferences, select the 3D Rendering tab and click on box Gaussian image smoothing and press Ok. Then in the 3D view, press update again.

## Step 8. Linked 3D and 2D Image Cursors

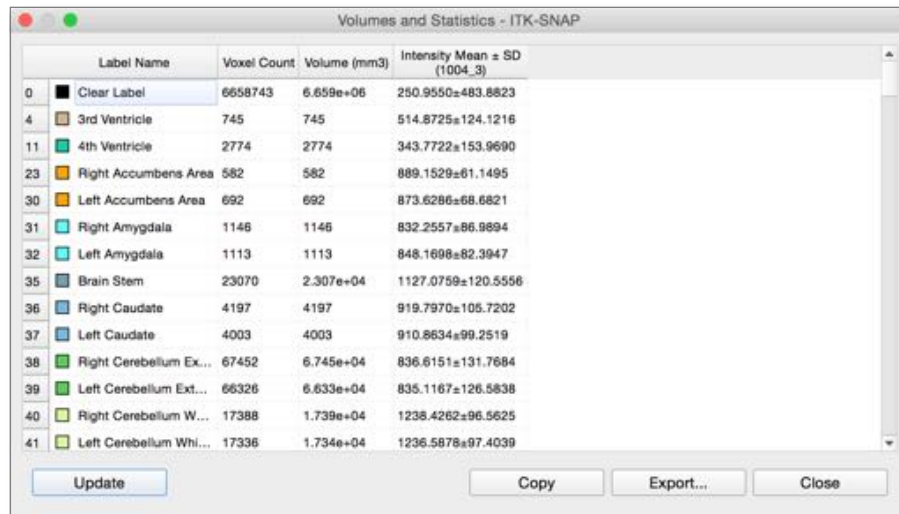
- In the 3D Toolbar at the lower left of the ITK-SNAP window, select the 3D Crosshair tool.



- Left-click on any of the structures in the 3D view.
  - The cursors in the 2D views will move to the location where you clicked.

## Step 9. Compute Volumes and Statistics

- In the main menu, select Segmentation->Volumes and Statistics



	Label Name	Voxel Count	Volume (mm3)	Intensity Mean ± SD (1004_3)
0	Clear Label	6658743	6.659e+06	250.9550±483.8823
4	3rd Ventricle	745	745	514.8725±124.1216
11	4th Ventricle	2774	2774	343.7722±153.9690
23	Right Accumbens Area	582	582	889.1529±61.1495
30	Left Accumbens Area	692	692	873.6286±68.6821
31	Right Amygdala	1146	1146	832.2557±86.9894
32	Left Amygdala	1113	1113	848.1698±82.3947
35	Brain Stem	23070	2.307e+04	1127.0759±120.5556
36	Right Caudate	4197	4197	919.7970±105.7202
37	Left Caudate	4003	4003	910.8634±99.2519
38	Right Cerebellum Ex...	67452	6.745e+04	836.6151±131.7684
39	Left Cerebellum Ext...	66326	6.633e+04	835.1167±126.5838
40	Right Cerebellum W...	17388	1.739e+04	1238.4262±96.5625
41	Left Cerebellum Whi...	17336	1.734e+04	1236.5878±97.4039

Update Copy Export... Close

What is the volume of the left hippocampus (label 48)?

\_\_\_\_\_ mm<sup>3</sup>

What is the average intensity of the left hippocampus?

\_\_\_\_\_

## Step 10. Unload the MRI image

- Close the Volumes and Statistics and Layer Inspector windows (if open)
- In the main menu, select File->Close All Images (shortcut **Shift-⌘W**)
- If asked to save your segmentation, press Don't Save
- Congratulations! You have completed Exercise 1.



## Exercise 2: Manual Segmentation

### Learning Objectives

After completing this exercise, you will know how to

- Load a DICOM image file
- Create and edit segmentation labels
- Outline structures of interest with the polygon tool
- Edit segmentations with the paintbrush tool
- [Optional] Use adaptive paintbrush for computer-aided segmentation

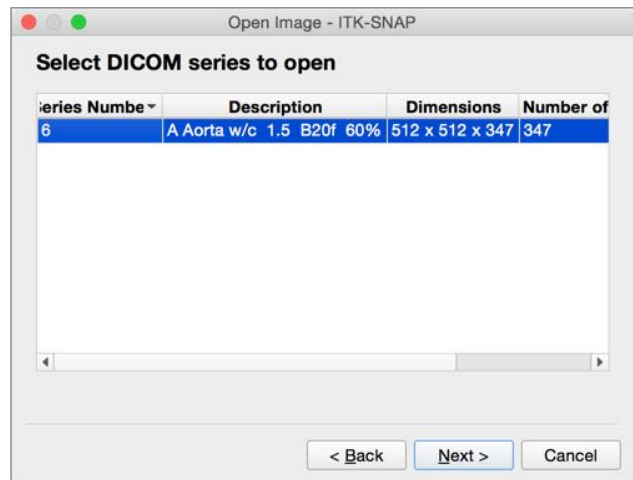
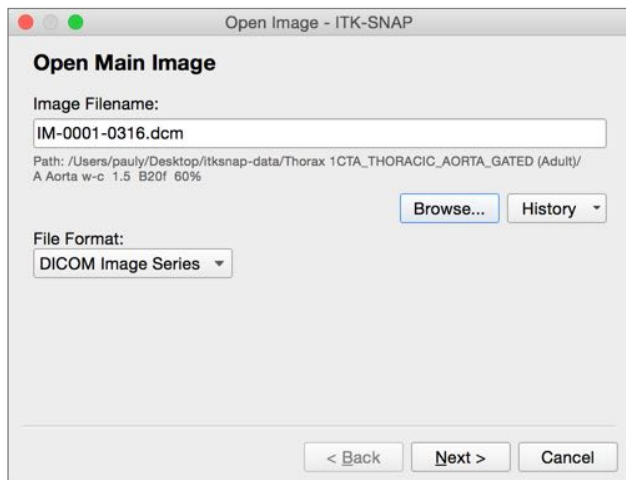
**Duration:** 15 minutes.

### Step 1. Load a body CT scan from a DICOM file

- From the main menu, select *File->Open Main Image* (shortcut ⌘G)
- Press *Browse*, then navigate to the folder below:

`Desktop/itksnap-data/Thorax 1CTA_THORACIC.../A Aorta w-c 1.5 B20f 60%`

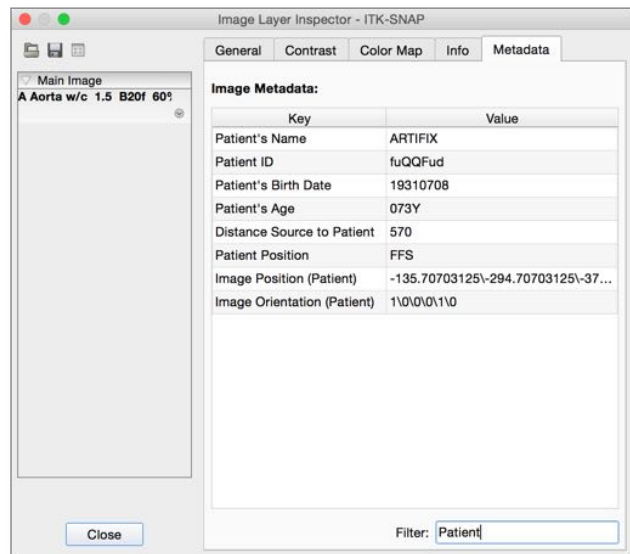
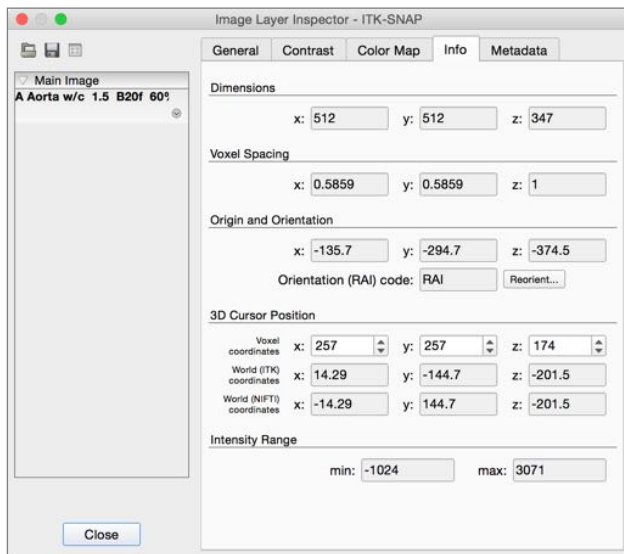
- Select the any file in that folder, e.g., `IM-0001-0001.dcm` and press *Open*
- The wizard should now look like the image on the left below:
  - Notice that the *File Format* has been automatically set to “DICOM Image Series”



- Press *Next*. A new screen will appear (above, right).
  - This screen shows all the DICOM series found in the folder
  - In this case, there is only one DICOM series found, and it is already selected.
- Press *Next* to show the summary page
- Press *Finish* to close the wizard

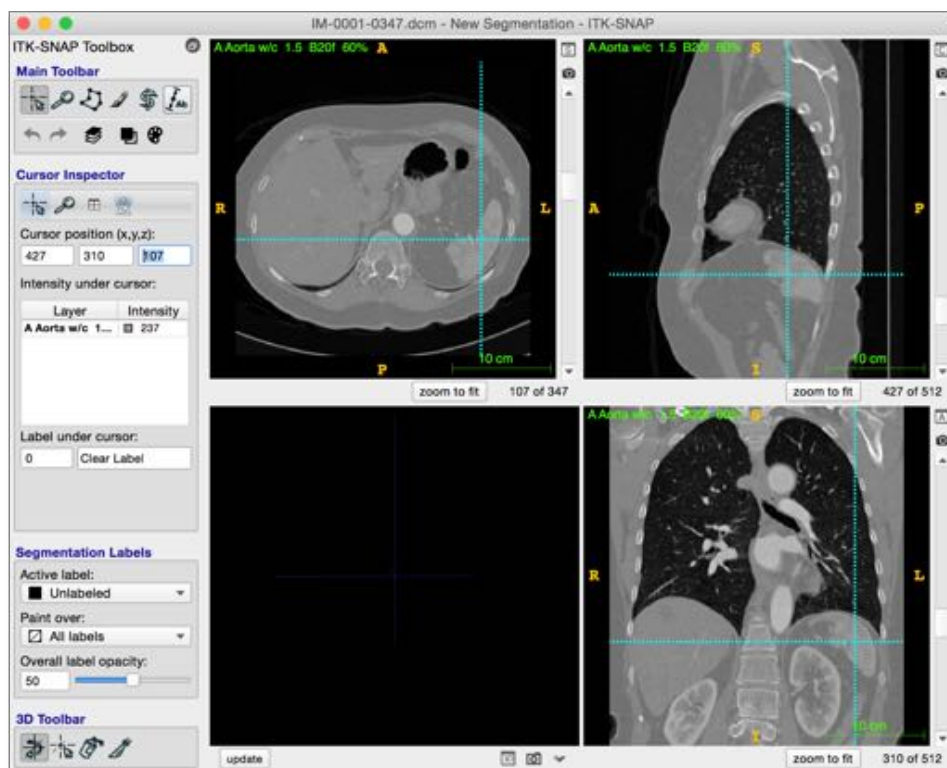
## Step 2. [Optional] View Image Information and DICOM Metadata

- Open the *Layer Inspector* (shortcut **⌘I**), and select the *Info* tab (below, left)
  - This lists basic information about the image, like its size, voxel dimensions, etc.
- Now select the *Metadata* tab (below, right)
  - This lists all the information contained in the image header
  - You can search for specific entries by typing in the *Filter* field



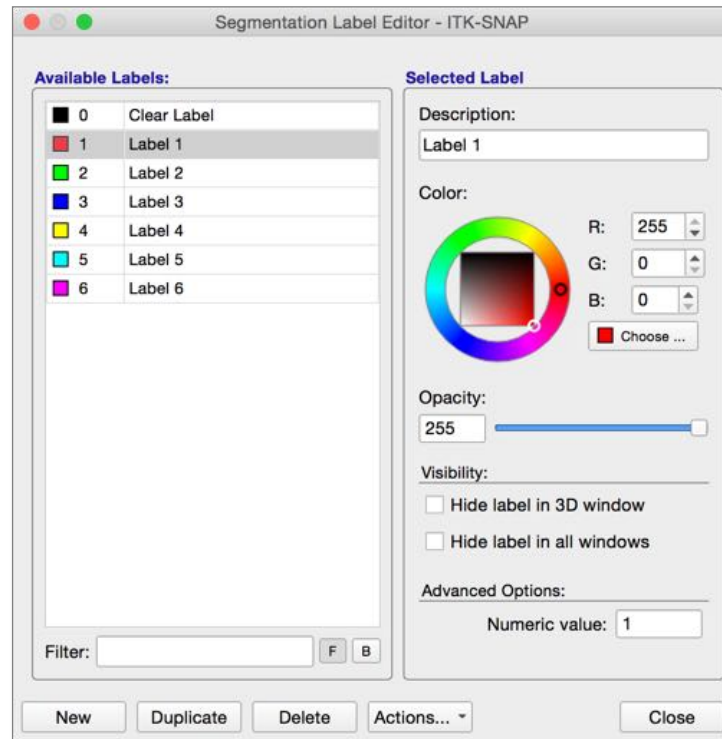
## Step 3. Locate the Spleen

- Automatically adjust the CT image contrast by pressing **⌘J**.
- Use the *Crosshair tool* (shortcut **1**) to find the spleen (as shown below)



#### Step 4. Create Anatomical Labels

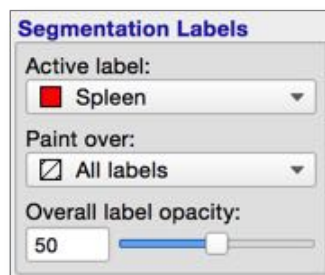
- In the main menu, select Segmentation->Label Editor (shortcut **⌘L**)
  - The label editor should contain seven labels with generic names, as shown below
  - If it does not (e.g., brain labels from the previous exercise are shown), reset the label list by pressing Actions button at the bottom of the window, and selecting Reset Label Descriptions



- Select Label 1 in the list on the left
- Under Description, type in “Spleen”
  - You may also want to change the color for the spleen label
- Create additional labels for left and right kidneys, liver, etc.
  - Use the New button if you decide to create more than 6 labels
- Close the Label Editor window

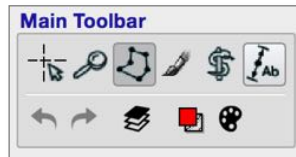#### Step 5. Select the Active Label

- In the Segmentation Labels panel, make sure that “Spleen” is selected as the Active Label.
  - Also ensure that “All Labels” is selected as the Paint over setting






## Step 6. Label the Spleen using the Polygon Tool

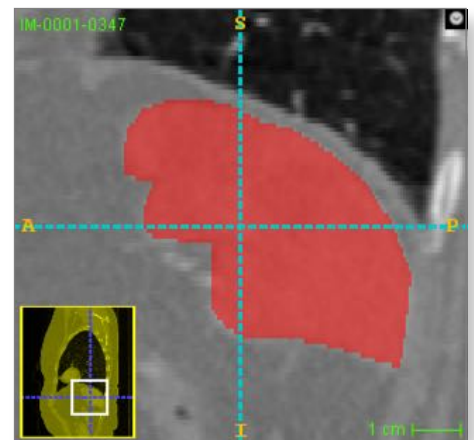


- Set the zoom factor to 2x and center the view on the spleen (zoom/pan was covered in Exercise 1)
- Select the Polygon Tool in the Main Toolbar (shortcut 3)



- Using a series of left clicks, draw the outline of the spleen in one of the slice views
- Finish drawing by clicking on the first point - the outline will turn red (below, right)
  - *Note: You can zoom and pan while drawing polygons without switching to another tool; just press the right mouse button and drag to zoom, and move the white square in the yellow thumbnail to pan.*

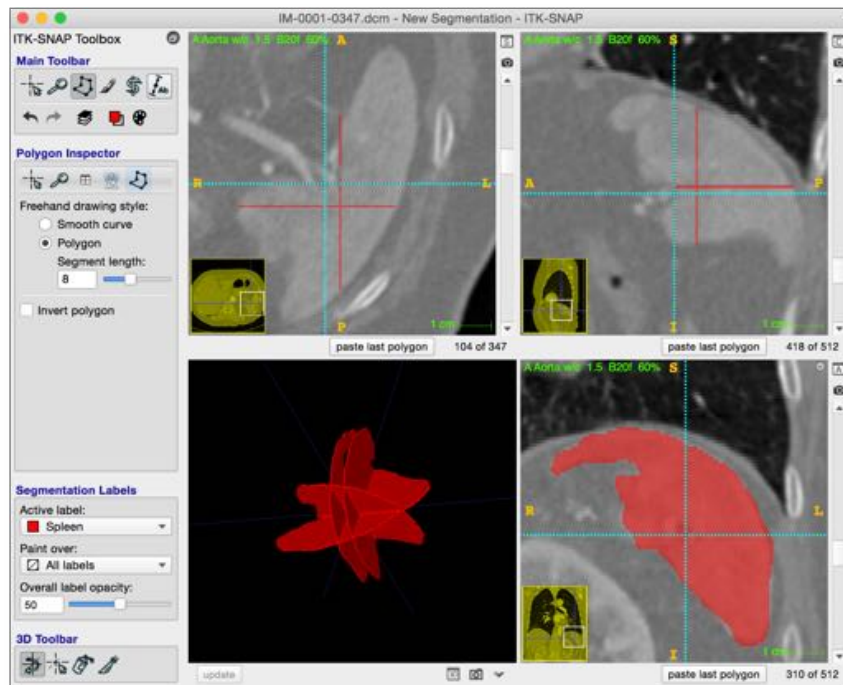


- If you wish to edit the contour, you can click and drag on individual point (below left), or draw an edit box around multiple points (below, middle).



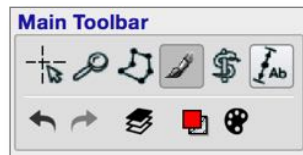- Once satisfied, press accept, and the contour will be integrated into the segmentation (above, right)
  - When you hit accept, all the voxels inside of the polygon are assigned the active label (Spleen)
  - ITK-SNAP represents segmentations by assigning each voxel a unique label
- Draw the spleen outline in other slice views (you won't have time to segment the entire structure of course, so just do as much as you need to get the hang of the polygon tool)

- Notice that once you accept a polygon in one slice view (e.g., sagittal), it becomes visible in the other slice views (coronal, axial)
- You can also render your partial segmentation in the 3D view by pressing update.

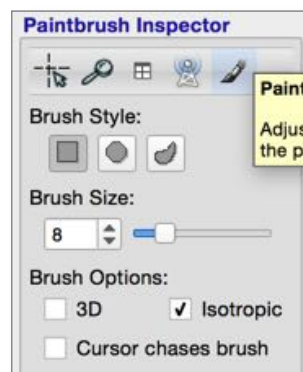


## Step 7. Draw small structures using the Paintbrush Tool

- In the Main Toolbar, select the Paintbrush Tool (shortcut 4).



- In the Paintbrush Inspector, under Brush Style, select the circle (round brush)
- Under Brush Options, check Isotropic



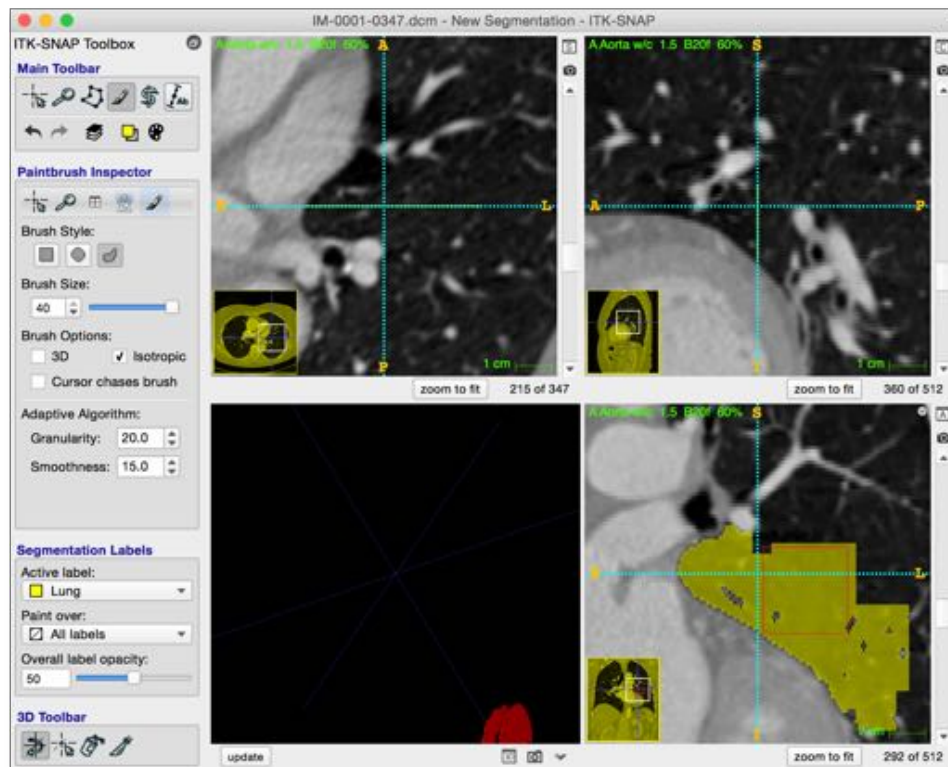
- Hold and drag the left mouse button to paint with the active label (spleen)
- Hold and drag the right mouse button to paint with the clear label (this is useful for erasing stray pixels in your segmentations).
- You can undo paint operations with the undo button on the Main Toolbar (shortcut ⌘Z)



## Step 8. [Optional] Use the Adaptive Brush Style

The adaptive brush style adapts the brush shape based on the image content. It can be used to quickly label parts of structures that are distinctive from surrounding structures

- Open the *Label Editor* (⌘L) and create a “Lung” label
- Select “Lung” as the *active label*
- Position the cursor at coordinate 360, 292, 215
  - To do this, you need to select the *Crosshairs Mode* to access the *Cursor Inspector*
- Center the view on the cursor (shortcut C)
- Select *Paintbrush Mode* (shortcut 4)
- In the *Paintbrush Inspector*, under *Brush Style*, select the last icon (adaptive brush)
- Set *Brush Size* to 40
- Click (do not drag) somewhere in the lung, close to other tissues.
  - Notice how just the lungs get painted with the lung color, while the surrounding tissue is not.
  - Changing the granularity and smoothness parameters changes adaptive brush behavior

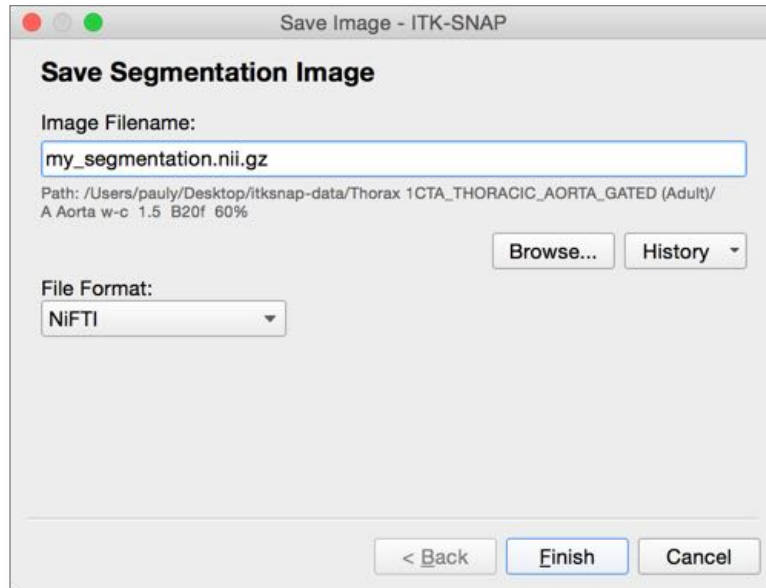




## Step 9. Save your segmentation

Segmentations in ITK-SNAP are saved as a special kind of image, where each voxel holds a value referencing an anatomical label.

- From the main menu, select Segmentation->Save Segmentation Image
- Select the file format for the segmentation (NIFTI is a good choice)
- Assign a filename and hit Finish



- Congratulations, you have finished Exercise 2!

## MODULE II: Semi-Automatic Segmentation

### Exercise 3: Basic Semi-Automatic Segmentation

---

#### Learning Objectives

In this exercise, we will use semi-automatic segmentation to label the spleen in the CT image from Exercise 2. After completing this exercise, you will know how to

- Perform semi-automatic segmentation on a single image
- Selects regions of interest for semi-automatic segmentation
- Use thresholding to pre-segment image into foreground and background
- Initialize the active contour using bubbles
- Perform contour evolution

**Duration:** 15 minutes.

#### Step 1. Open the CT DICOM File from Exercise 2

For this exercise, we will continue working with the same CT dataset as in exercise 2. If you already have it opened, continue to the next step.

- Load the CT image from

`Desktop/itksnap-data/Thorax 1CTA_THORACIC.../A Aorta w-c 1.5 B20f 60%`

- If you completed Exercise 2, then this image will be in your recent image history. Access it by selecting from the main menu *File->Recent Main Images->[Image Name]*
- If you did not complete Exercise 2, see Step 1 in Exercise 2.

#### Step 2. Unload previous segmentation

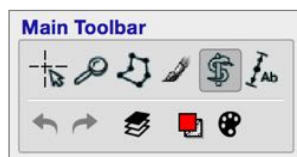This step clears the segmentation you created in Exercise 2.

- From the main menu, select *Segmentation->Unload Segmentation*.
- If prompted to save the segmentation, press *Discard*.

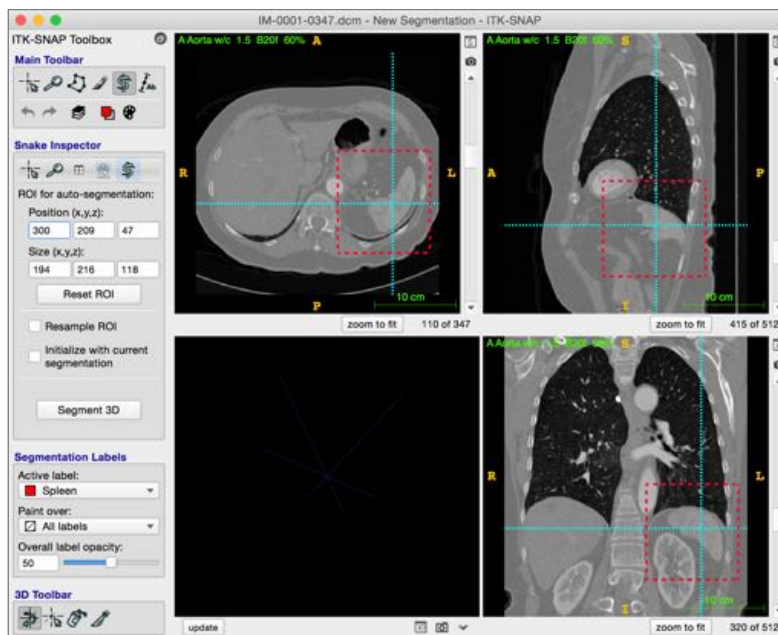
#### Step 3. Select Region of Interest for Automatic Segmentation

This is a preparatory step for semi-automatic segmentation.

- From the main menu, select *Edit->View Zoom->Zoom to Fit in All Views* (**⌘F**), which will make the whole CT image visible in all three slice views
- Make sure “Spleen” is selected as the *Active Label*
- Position the 3D crosshairs in the center of the spleen (e.g., coordinates 415,320,110)
- In the *Main Toolbar*, select the snake-looking *Active Contour Tool* (shortcut **5**).




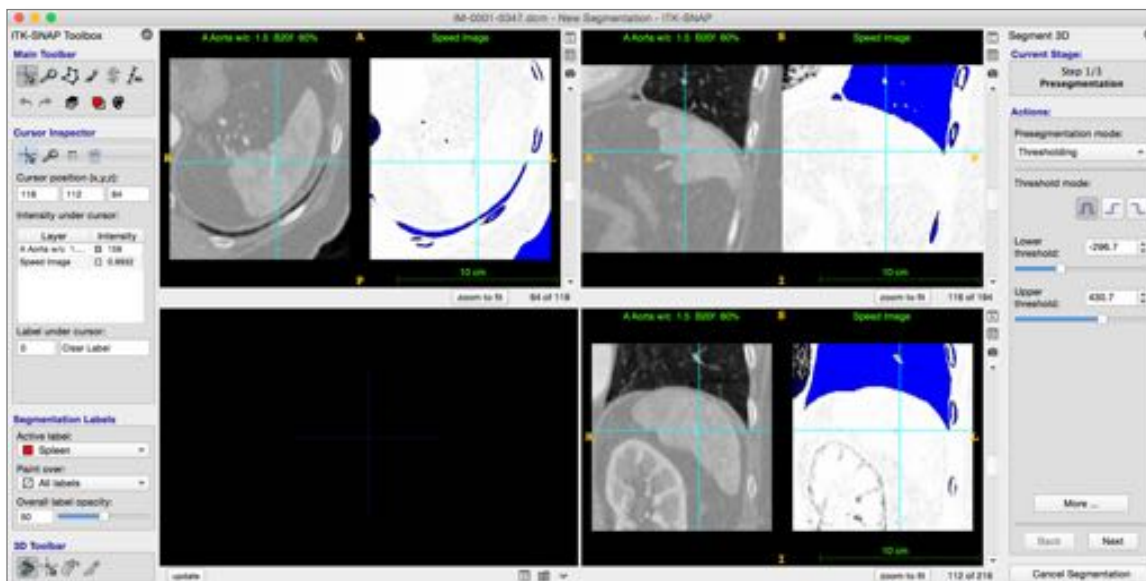
- Using the left mouse button, drag the corners of the red selection box, so that the box encompasses the spleen, as shown below
- Or you can type in the position (300,209,47) and size (194,216,118) of the selection box in the Snake Inspector, as highlighted below



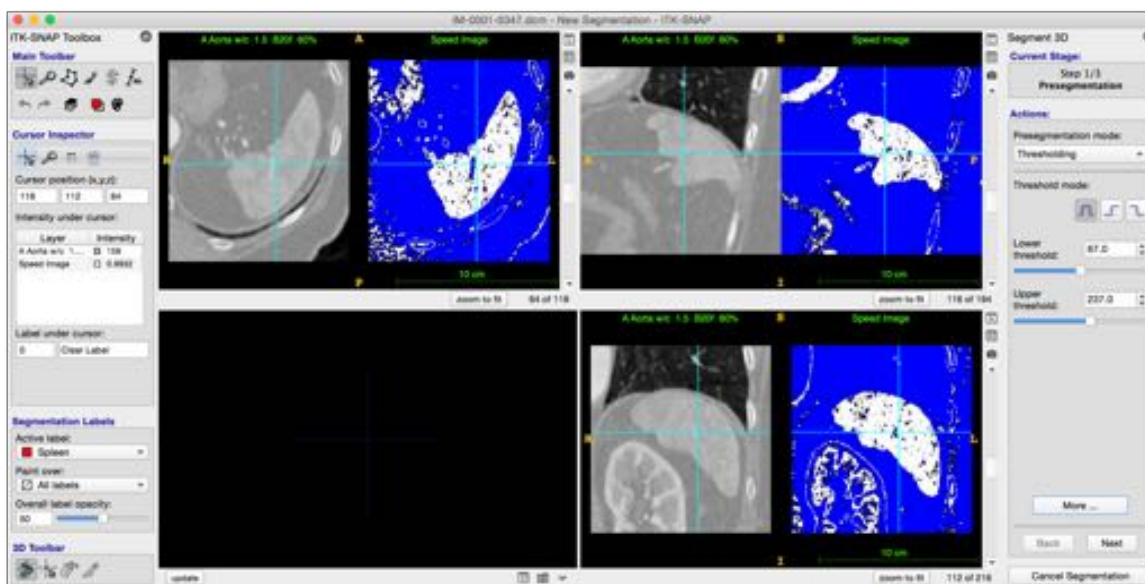
- Press Segment 3D to enter the semi-automatic segmentation mode.

#### Step 4. Use Thresholding to Isolate the Spleen

- Your ITK-SNAP window should look like the screenshot below. Each slide view will show two images side by side. On the left is the region of interest of the CT, and on the right is the so-called *speed image*, which should be white in spleen voxels, and blue in non-spleen voxels.
- If your images are not shown side by side as below, press the little button  in the right top corner of any of the three slice views (shortcut  $\backslash$ ).
- If the CT image contrast looks wrong, select Tools->Image Contrast->Auto Adjust Contrast ( $\text{⌘J}$ ).



- In the tool panel on the right hand side of the ITK-SNAP window, ensure that under Actions, the Presegmentation Mode is set to “Thresholding”
- Use the Lower threshold and Upper threshold sliders to make the speed image as **white as possible in the spleen** and as **blue as possible outside of the spleen**, as shown:
  - We recommend 67 and 237 as the threshold values

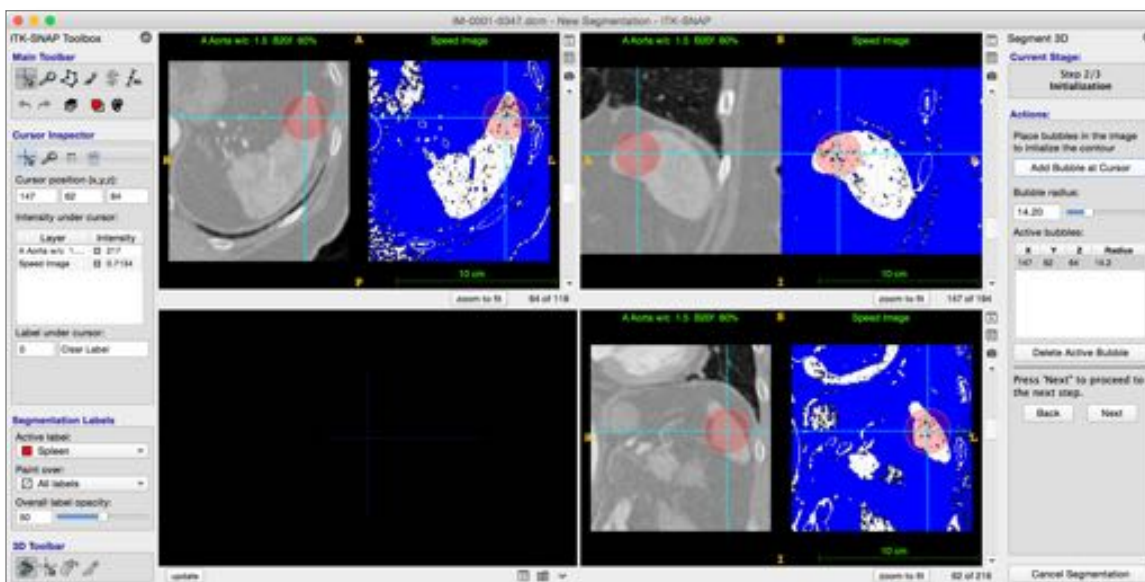


- When satisfied, press Next in the right-hand panel to continue

## Step 5. Place initialization bubbles in the spleen

You are now in “Initialization” mode, where you place bubbles to initialize the active contour.

- Position the 3D crosshair in the left anterior portion of the spleen (shown below)
- Under Actions, press Add Bubble at Cursor to insert an initialization bubble (shown below)



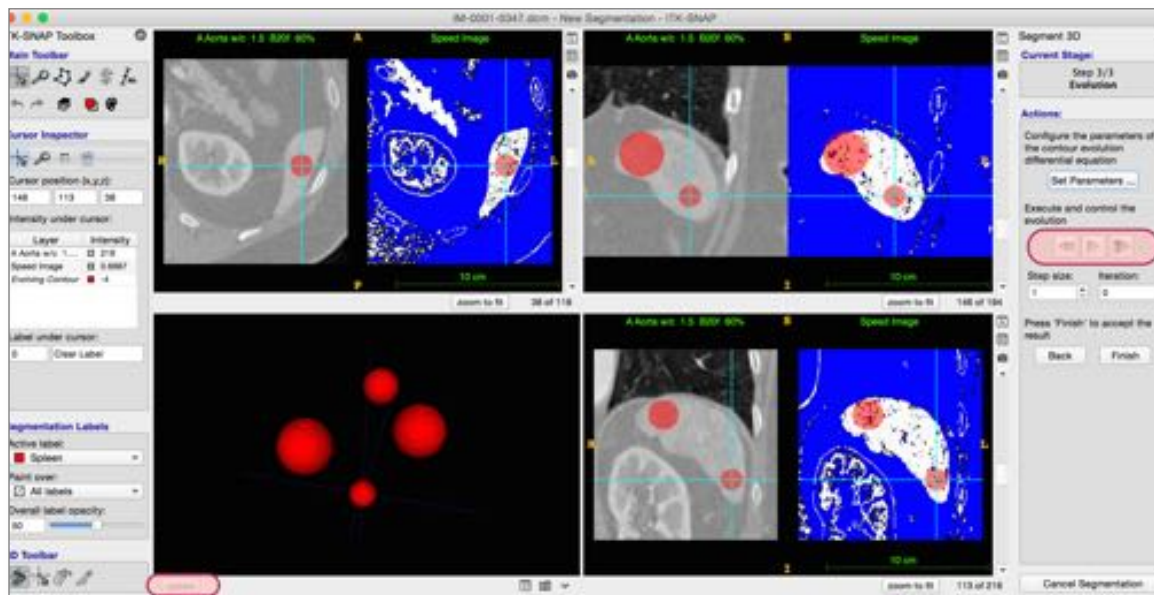
- Repeat, inserting 2-3 more bubbles in different parts of the spleen
- When ready, press Next to continue



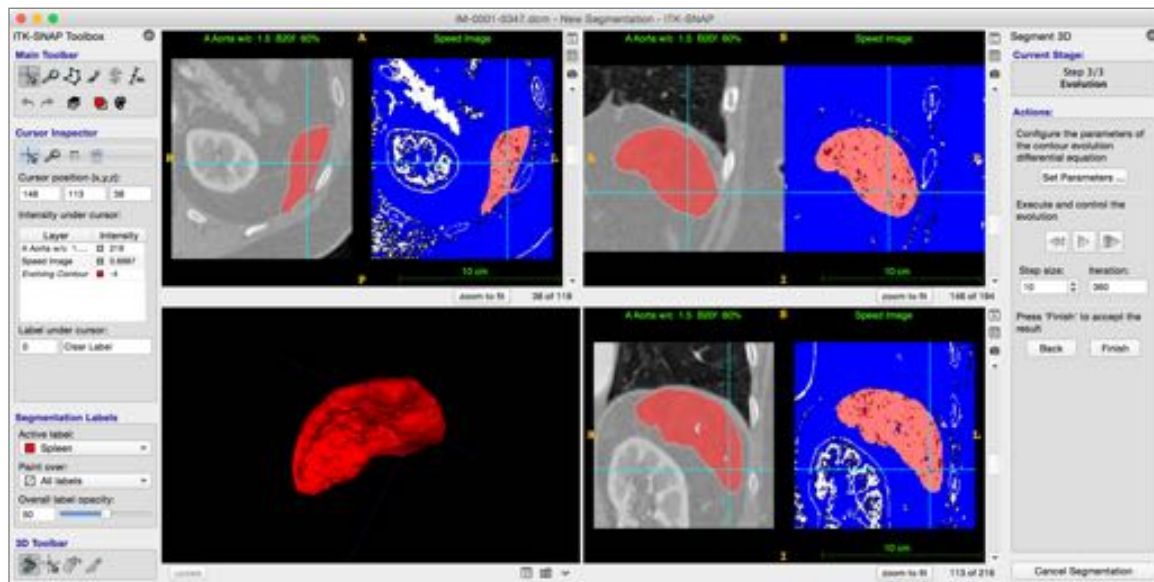
## Step 6. Run active contour segmentation

You are now in “Evolution” mode, where you let the bubbles grow to fill the spleen.

- In the 3D visualization panel (lower right quadrant), press update to visualize the bubbles



- Under Actions, press the play button (▶) to start evolution (highlighted above).
  - As the contour evolves, you can press update in the 3D visualization panel to get a rendering
- After about 350 iterations, press the pause button (⏸) under Actions to stop evolution

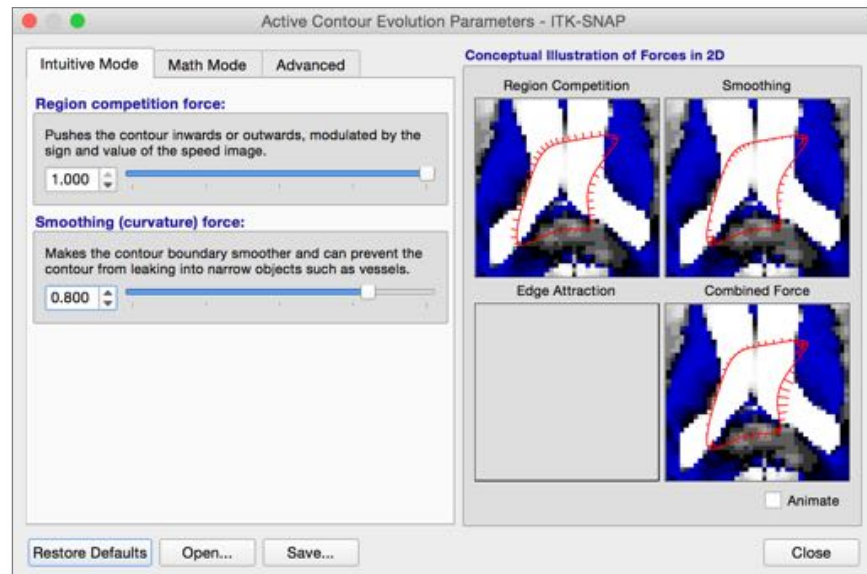


- If you are not satisfied with the segmentation, you may press the Back button to return to the pre segmentation and initialization stages, and use different threshold values or bubble placement.

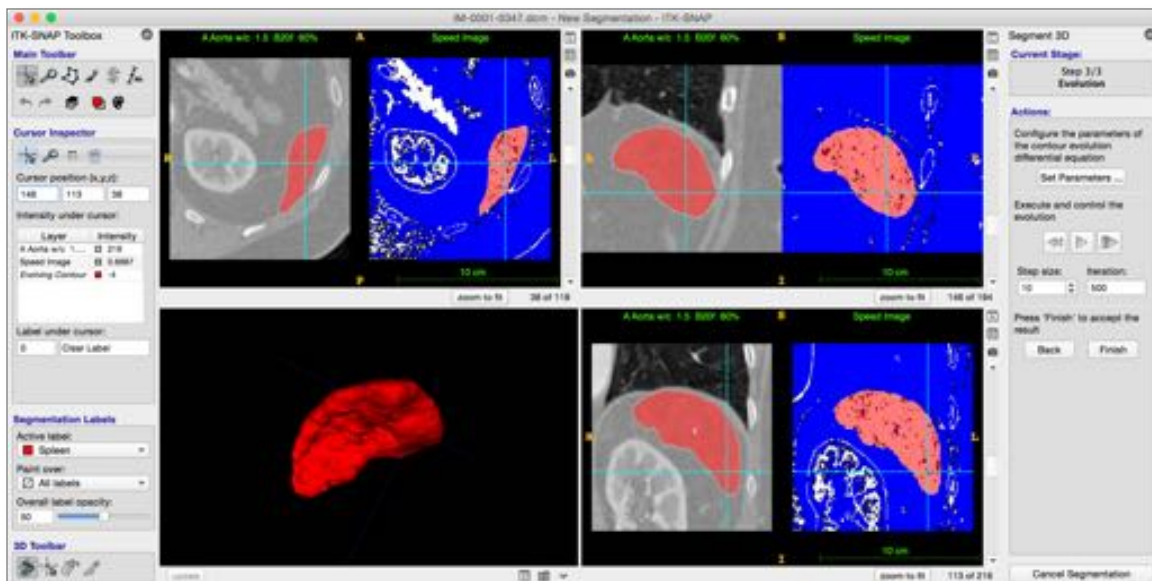
## Step 7. [Optional] Repeat segmentation with different parameters

To obtain a smoother spleen segmentation, we can change the parameter that controls smoothness.

- Under Actions, press Set Parameters button
- In the window that opens (see below), set a larger (0.8) value of the Smoothing (curvature) force,



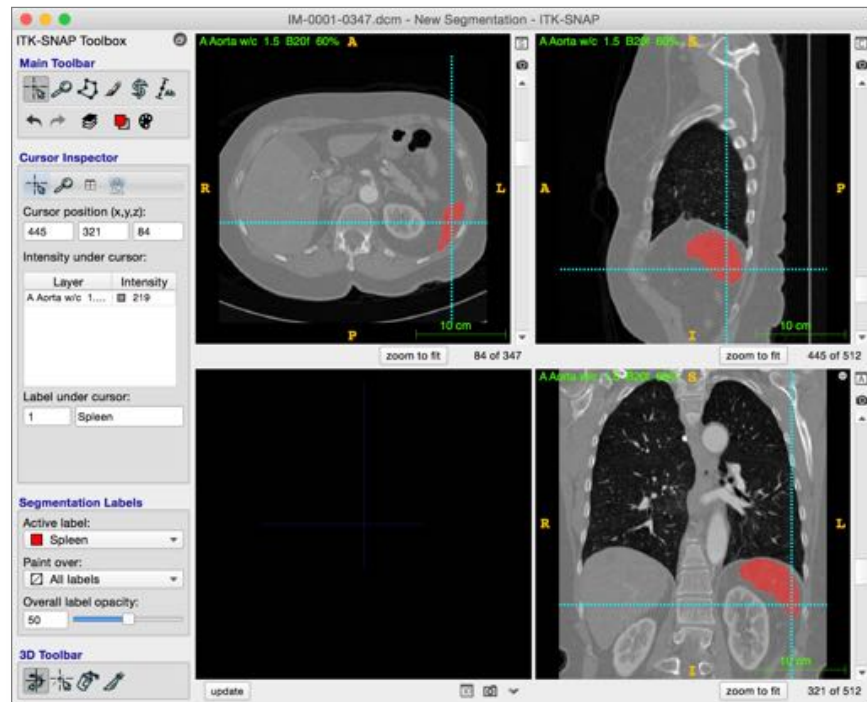
- Press Close to close the window.
- Rewind the segmentation (⏮), and run again for several hundred iterations.





## Step 8. Exit semi-automatic segmentation mode

- Under *Actions*, press the *Finish* button. Your segmentation of the spleen will be integrated into the overall segmentation of the CT image.
  - You can now repeat this process for various other structures in the CT scan



- Congratulations, you completed Exercise 3!

## Exercise 4: Multi-Modality Semi-Automatic Segmentation

### Learning Objectives

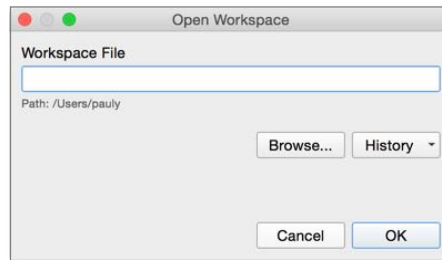
In this exercise, we will use semi-automatic segmentation to label a brain tumor from multiple MRI contrasts of the same subject.

- Open ITK-SNAP workspaces
- Work with multiple images at once
- Use the “classification” pre-segmentation mode to generate speed images

**Duration:** 15 minutes.

### Step 1. Open an ITK-SNAP workspace with multiple image files

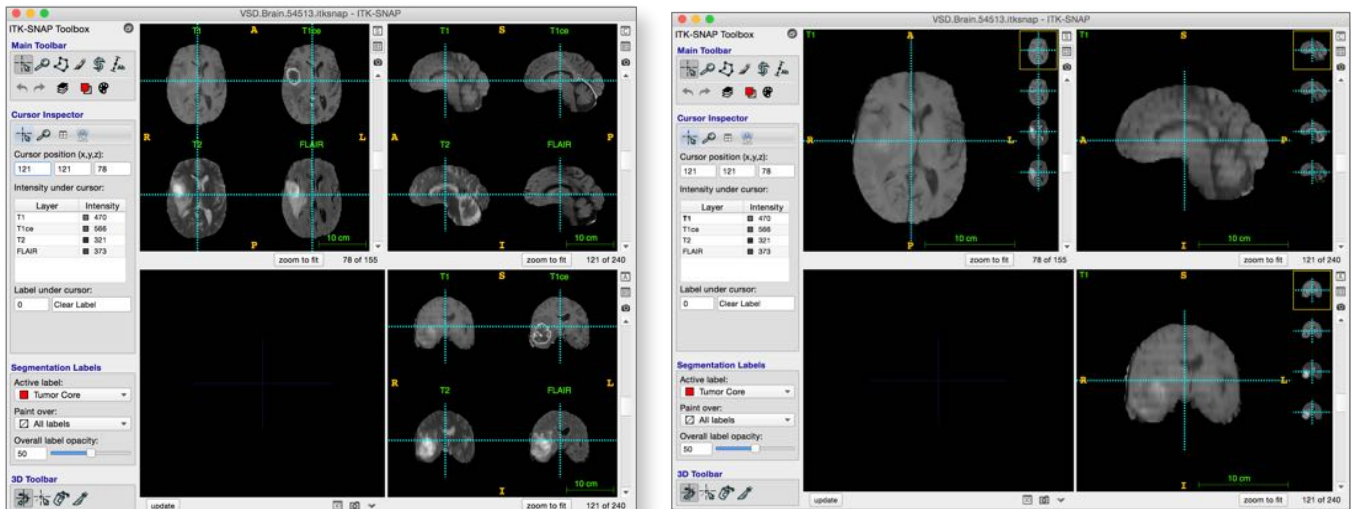
- From the main menu, select *Workspace->Open Workspace*.
- If prompted to save unsaved changes, press *Don't Save*.
- In the *Open Workspace* dialog window (below), press *Browse*





- Locate the workspace file for this exercise:


**Desktop/itksnap-data/VSD.Brain.54513/VSD.Brain.54513.itksnap**

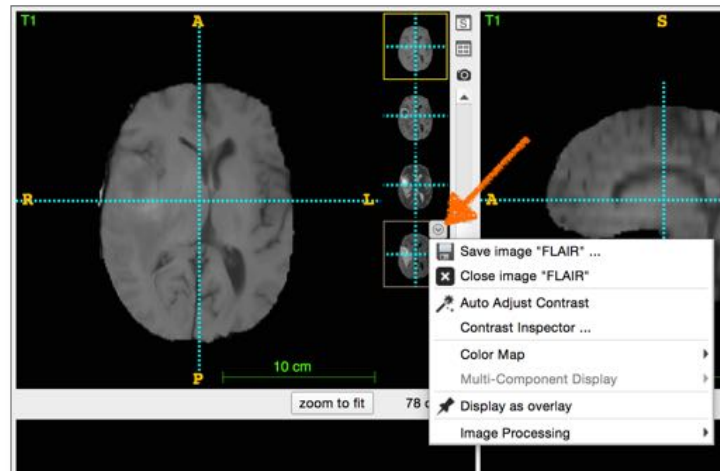
- Press Ok to open the workspace. Your screen will look like one of the images below:




- The layout on the left is called “Tiled layout” and the layout on the right is “Thumbnail layout”.
- Toggle between these layouts using the buttons  and  on the top right area of each slice panel

## Step 2. Experiment with the Thumbnail layout

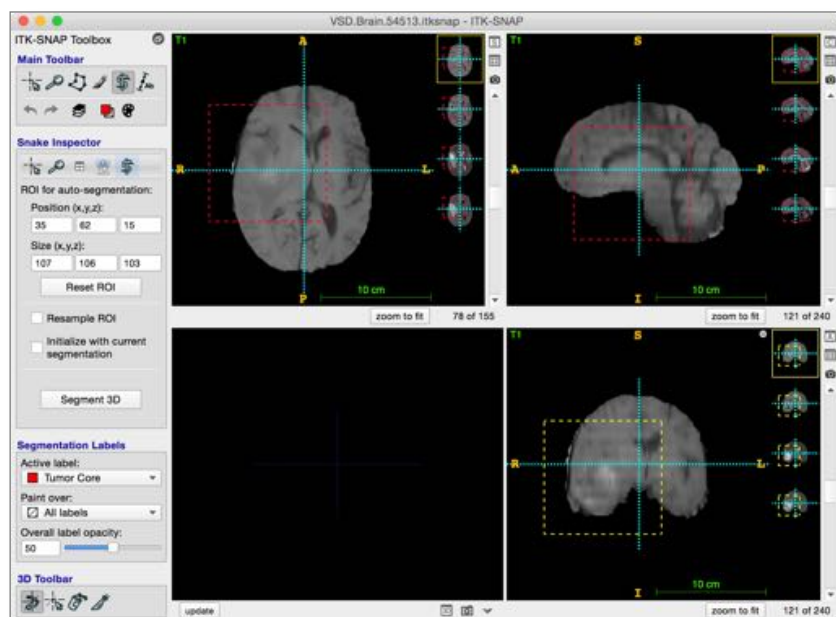
- Enter the “Thumbnail layout” by pressing the  button in one of the slice panels
- Press on the thumbnails on the right hand side of each slice view to select the different MRI contrasts
- When your mouse is over a thumbnail, you will see a small round button appear (indicated by orange arrow below). Press it to reveal a context menu for that image.



- Use the context menu to adjust the contrast and color map of the different images.
  - Or press  to auto-adjust contrast in all images

## Step 3. Select the Region of Interest for Tumor segmentation


- In the *Main Toolbar*, select the snake-looking *Active Contour Tool*.
- The region of interest will become visible. It is predefined in the workspace file that you loaded.
  - [Optional] check that the tumor is included in the region of interest for all modalities. Do do this, for each modality take turns selecting it, and then scroll through the different image slices to make sure the tumor and surrounding edema are in the region of interest. Adjust the region if needed.

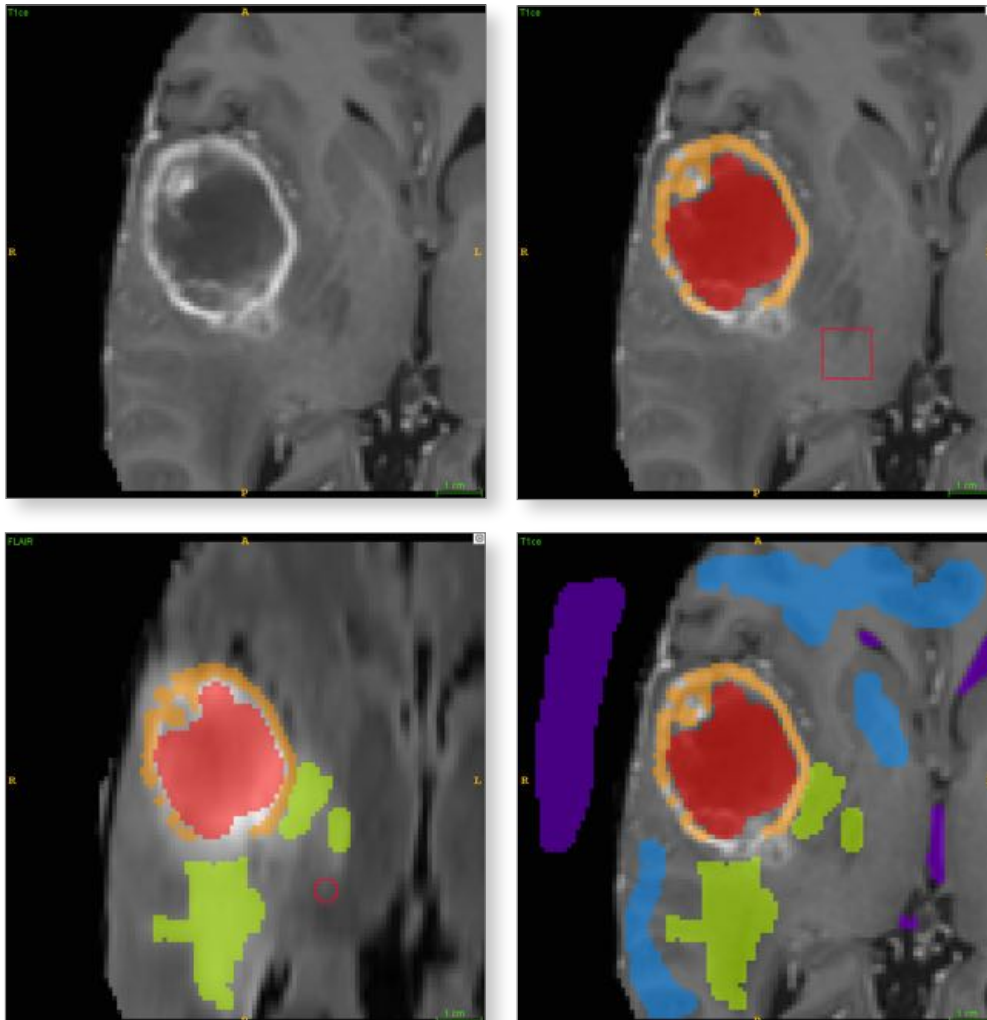


- Press *Segment 3D* to enter semi-automatic segmentation mode

#### Step 4. Pre-segmentation using classification

In this step, instead of thresholding used in Exercise 3, we will provide ITK-SNAP with examples of different tissue types in the image.

- Under Actions, set Presegmentation Mode to “Classification”
- The panel will look like what is shown on the right
  - Hover the mouse over the little color buttons in the panel. You will see that each one corresponds to an anatomical label.
  - Pressing the colored buttons will select set its label as the Active label and will also select the Paintbrush tool in the Main Toolbar.
- Using the buttons, paint examples of each tissue class in the image.
  - The contrast-enhanced “T1ce” image (top right in figure below) is best suited for labeling examples of the **tumor core** and **enhancing tumor**.
  - The FLAIR image (bottom left) is good for drawing examples of **edema**
  - The adaptive paintbrush  is helpful for drawing examples of the enhancing part of the tumor, which is thin.
  - See examples below of progressive labeling of tumor core, enhancing tumor, edema, normal brain, and other (fluid, non-brain region)
  - It is easiest to draw all your examples on just one slice, as we did below



Current Stage:  
Step 1/3  
Presegmentation

Actions:  
Presegmentation mode:  
Classification

Provide examples of two or more tissue classes by selecting the labels below and drawing on the image using the paintbrush tool.

Clear Examples

Next, train the classifier and select the tissue class that you wish to use for segmentation.

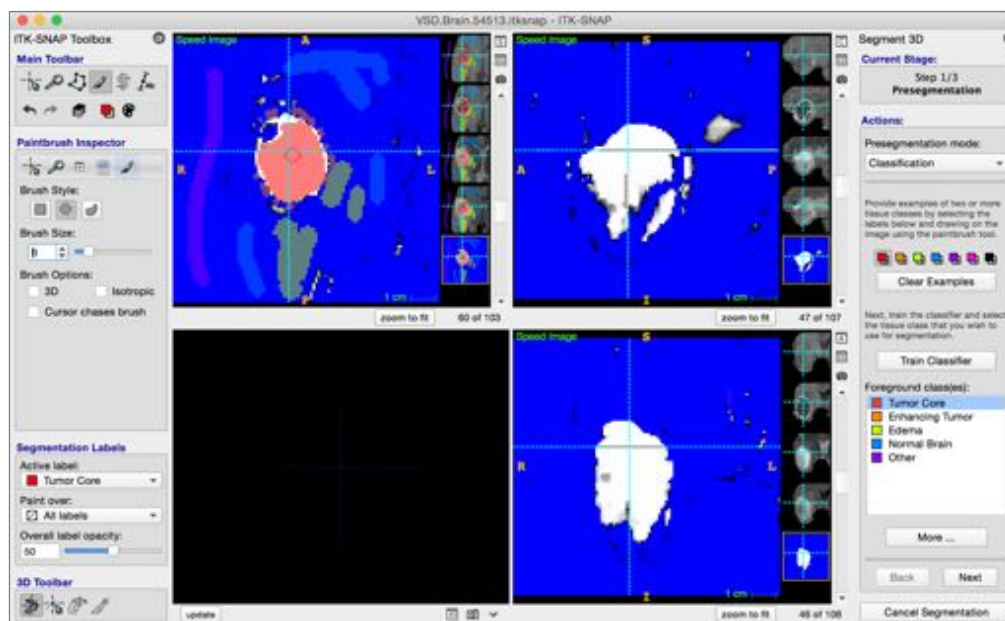
Train Classifier

Foreground class(es):

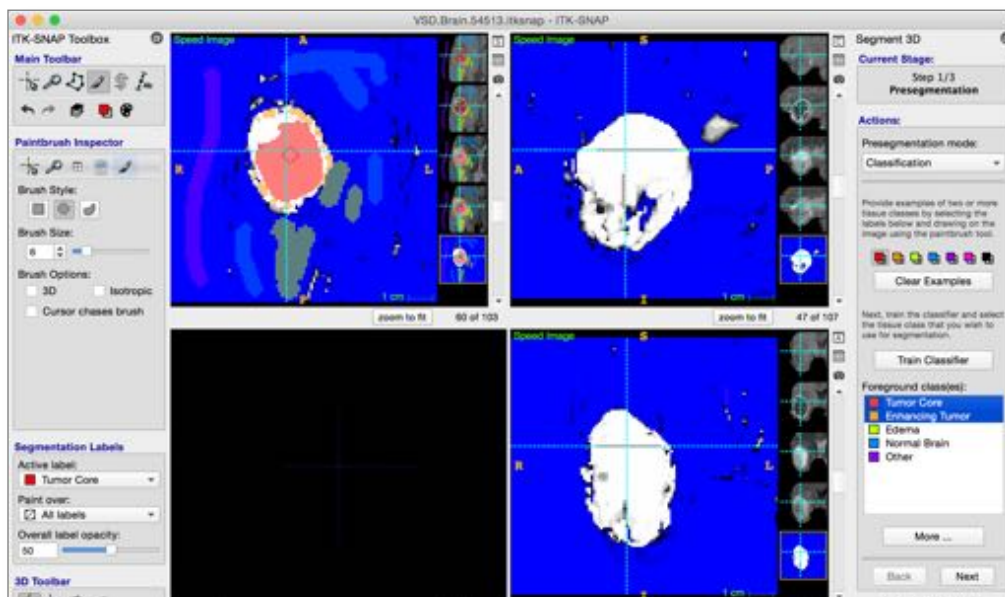
More ...

Back Next

- Press Train Classifier.
- Press the thumbnail for the speed image. Your window should look like what you see below.



- Press on different labels listed in the Foreground class(es) box. For each class you click on, a different speed image will appear.
  - Flip between the speed image and the different MRI images. If you think the speed image is incorrect, you can edit your examples and train the classifier again
- Now, using Shift-click to select both “Tumor Core” and “Enhancing Tumor” in the Foreground class(es) box
  - The reason we do this is that it is easier to first segment the two parts of the tumor together and then separate out the tumor core, than to segment the thin narrow enhancing tumor region independently.

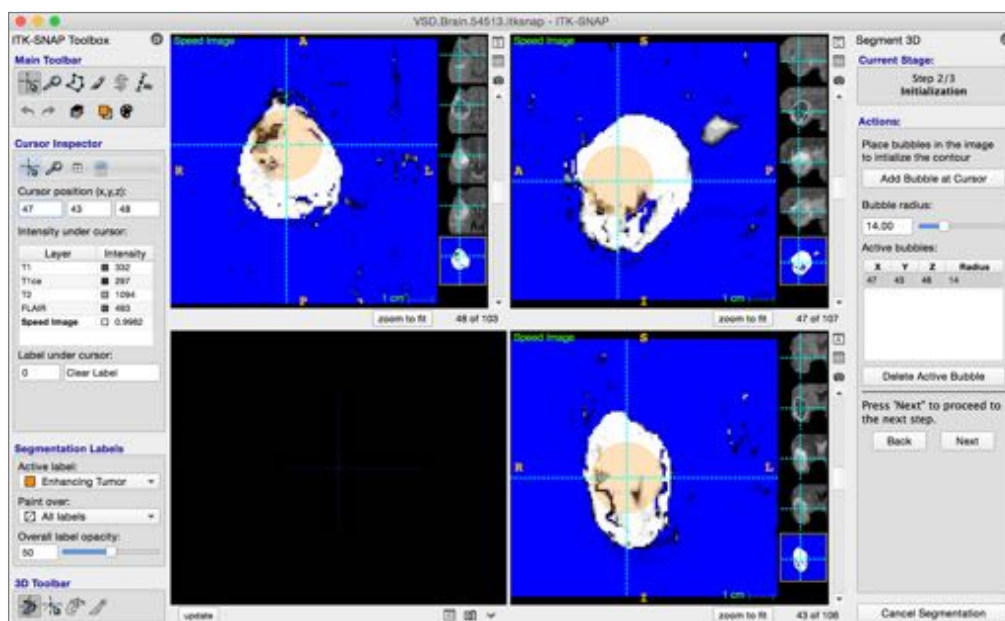


- Press Next in the right panel.

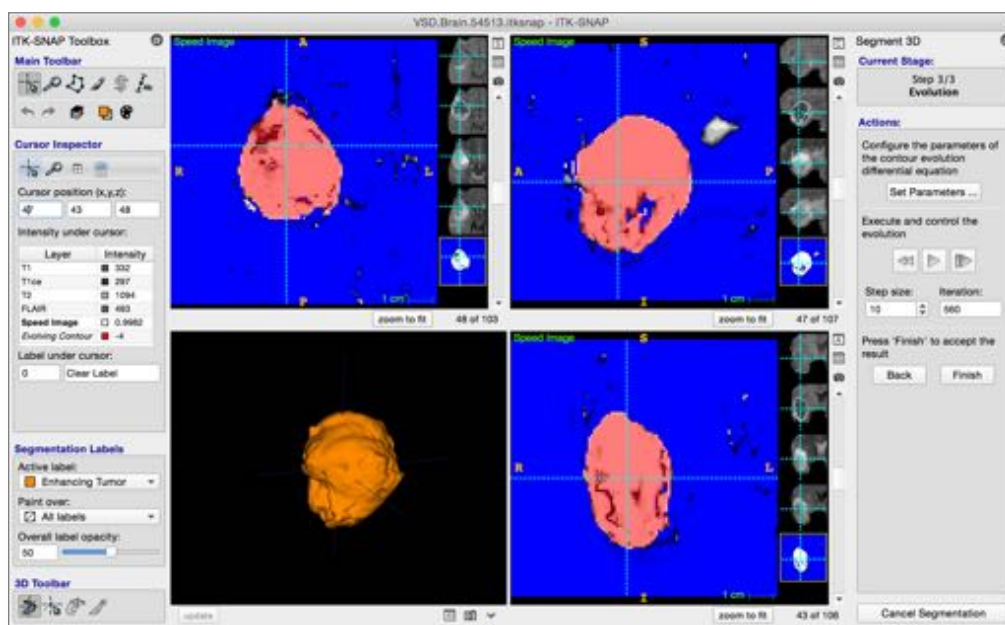
## Step 5. Perform Active Contour Segmentation



- Select “Enhancing Tumor” as the active label (left panel, *Segmentation Labels*)
- Place a single bubble in the bright region of the speed image.
- Press Next



- Run the segmentation as you did in Exercise 3.

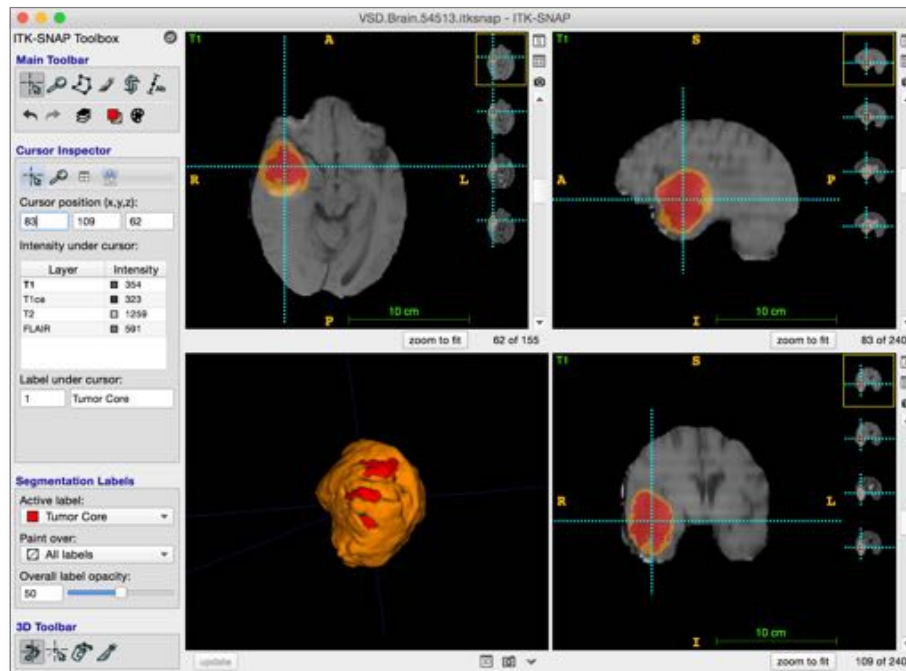


- Press Finish to send the segmentation into the main ITK-SNAP window.



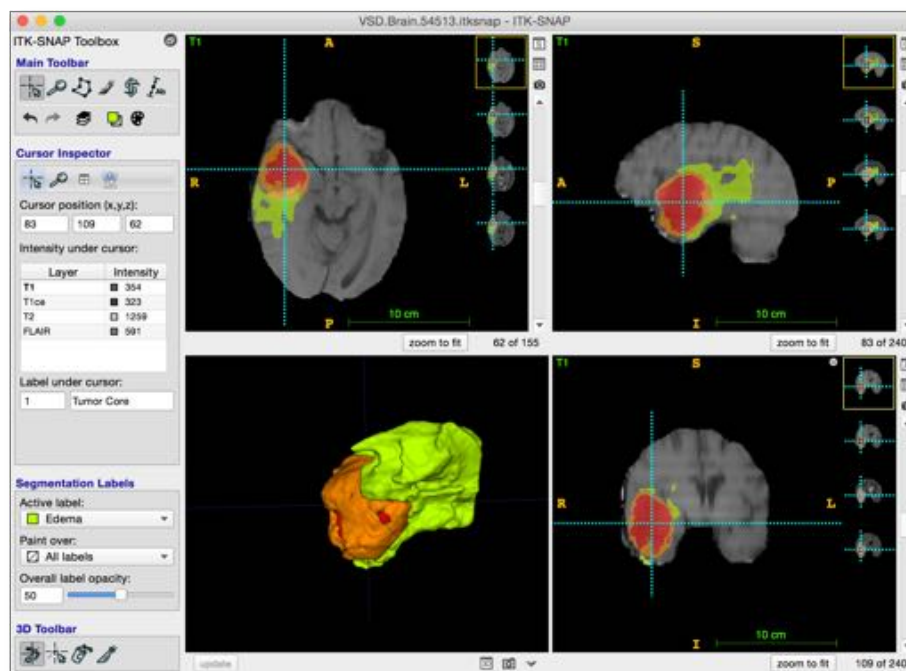
## Step 6. Repeat segmentation for the tumor core

- In the *Main Toolbar*, select the snake-looking *Active Contour Tool*, and press *Segment 3D*.
  - Notice how the examples you previously drew are still there
- Select “Tumor Core” in the *Foreground classes* box
- **Important:** Select “Tumor Core” as the active label
- Perform segmentation of the tumor core as in Step 5.
- When you finish, the segmentation should look like this



## Step 7. Repeat segmentation for the edema

- Follow the same sequence of steps to label edema






## Conclusions

---

By now, you have discovered the most widely used features of ITK-SNAP. The combination of semi-automatic and manual segmentation tools you have used should make it possible to solve a broad range of segmentation problems using ITK-SNAP.

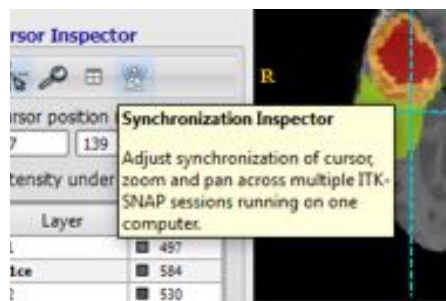
There are several additional tools and functionalities that ITK-SNAP provides. We did not have time to cover all of them in these exercises, and we invite you to explore them on your own. These features include:

- Interactive editing of semi-automatic segmentations.
- Using the 3D editing tools like the 3D scalpel ()
- Using different color maps to display images (*Tools->Color Map Editor...*)
- Displaying images (e.g., statistical maps) as overlays on top of other images (*Display as Overlay* in layer context menu)
- Saving screenshots ( or *File->Export->Screenshot*)
- Export segmentations as surface meshes, e.g., for 3D printing (*Segmentation->Export As Surface Mesh*)
- Additional pre-segmentation modes (edge-based and clustering-based)
- Annotation mode () , used to draw lines, measure lengths, and add comments to images
- Working with multiple ITK-SNAP sessions at once (*File->New ITK-SNAP Window*)
- Performing manual and automatic registration between images (*Tools->Registration*)
- Interpolating manual segmentation between slices (*Tools->Interpolate Labels*)

## Where to Find More Information?

---

Almost every button, checkbox, and control in ITK-SNAP has a tool tip. Hold your mouse cursor over the button for a second or two, and a tooltip will appear. Using these tooltips is one of the best ways to discover new features.



The [itksnap.org](http://itksnap.org) website is a source of additional information. Through the website you can find:

- [Video tutorials](#) from a day-long training course
- [Discussion boards](#) for ITK-SNAP users and developers
- Information on the companion image processing tool [Convert3D](#)